


**DDS Filippo Cardarelli**  
**Dentist**

*Specialist in Orthodontics*  
*University of Milan*



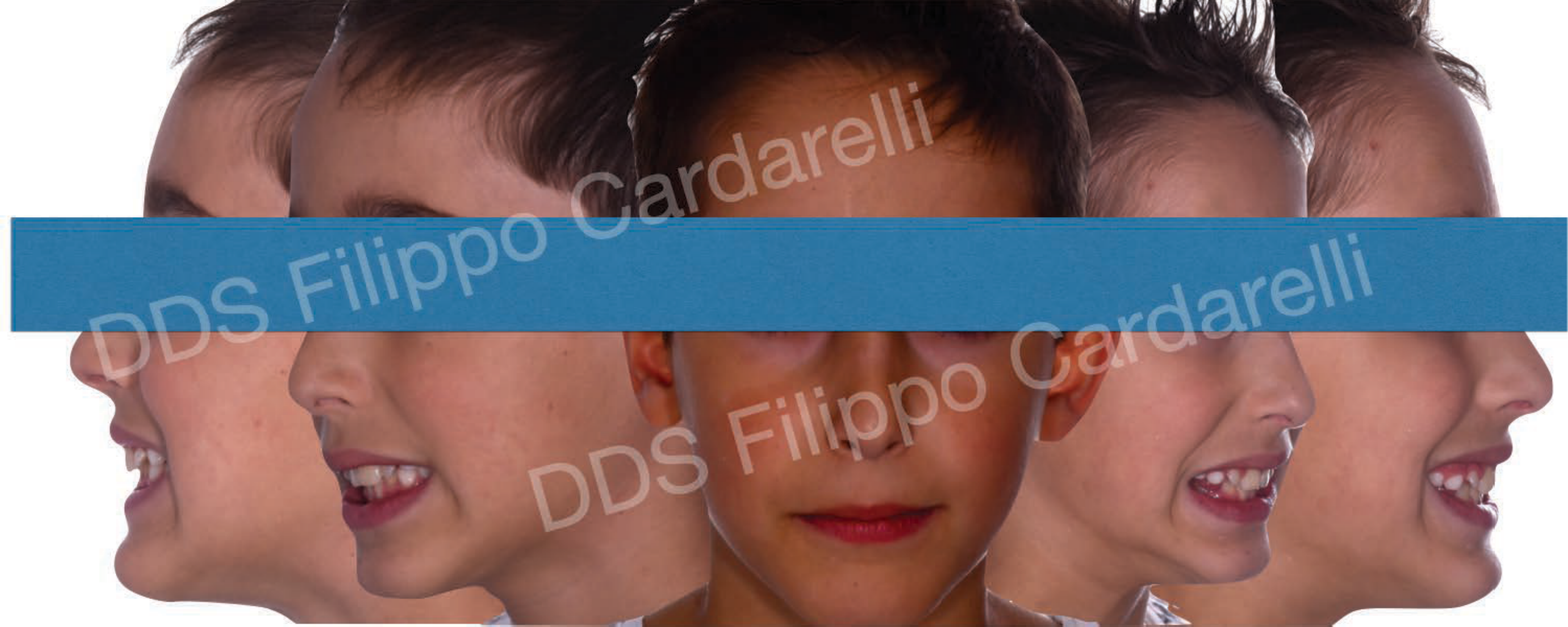# I<sup>st</sup> Skeletal class

Patient age 7 years , I skeletal class, tendency to hyperdivergence, vestibularization of upper incisors, upper dental misalignment. Malocclusion is associated with altered premaxilla shape with respiratory problems.

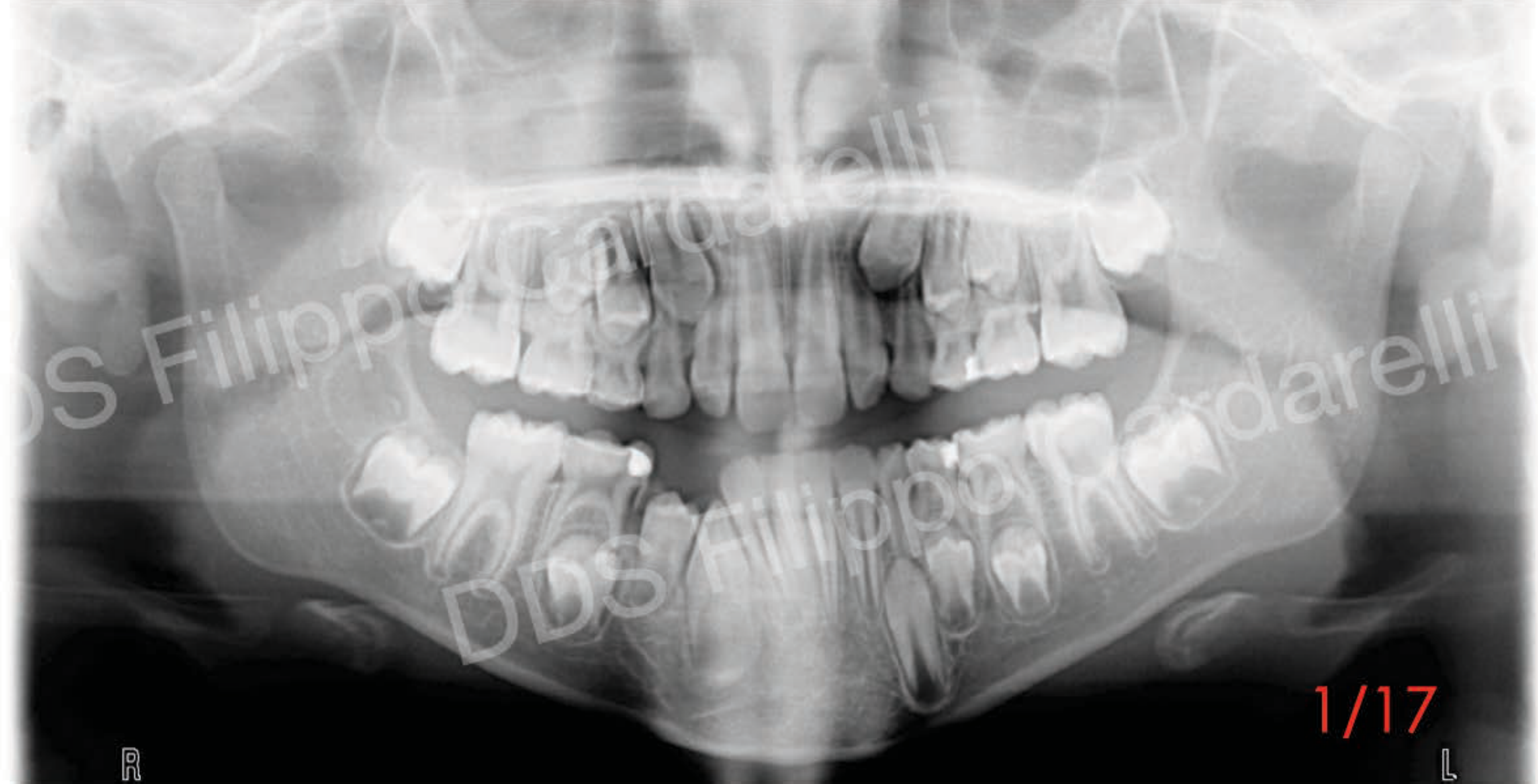
**The therapeutic sequence involves the following steps:**

- elastodontic therapy c n Amcop Integral for 16/18 months
- Speech therapy
- Physiotherapy/ osteopathy
- Gernectomy 38-48

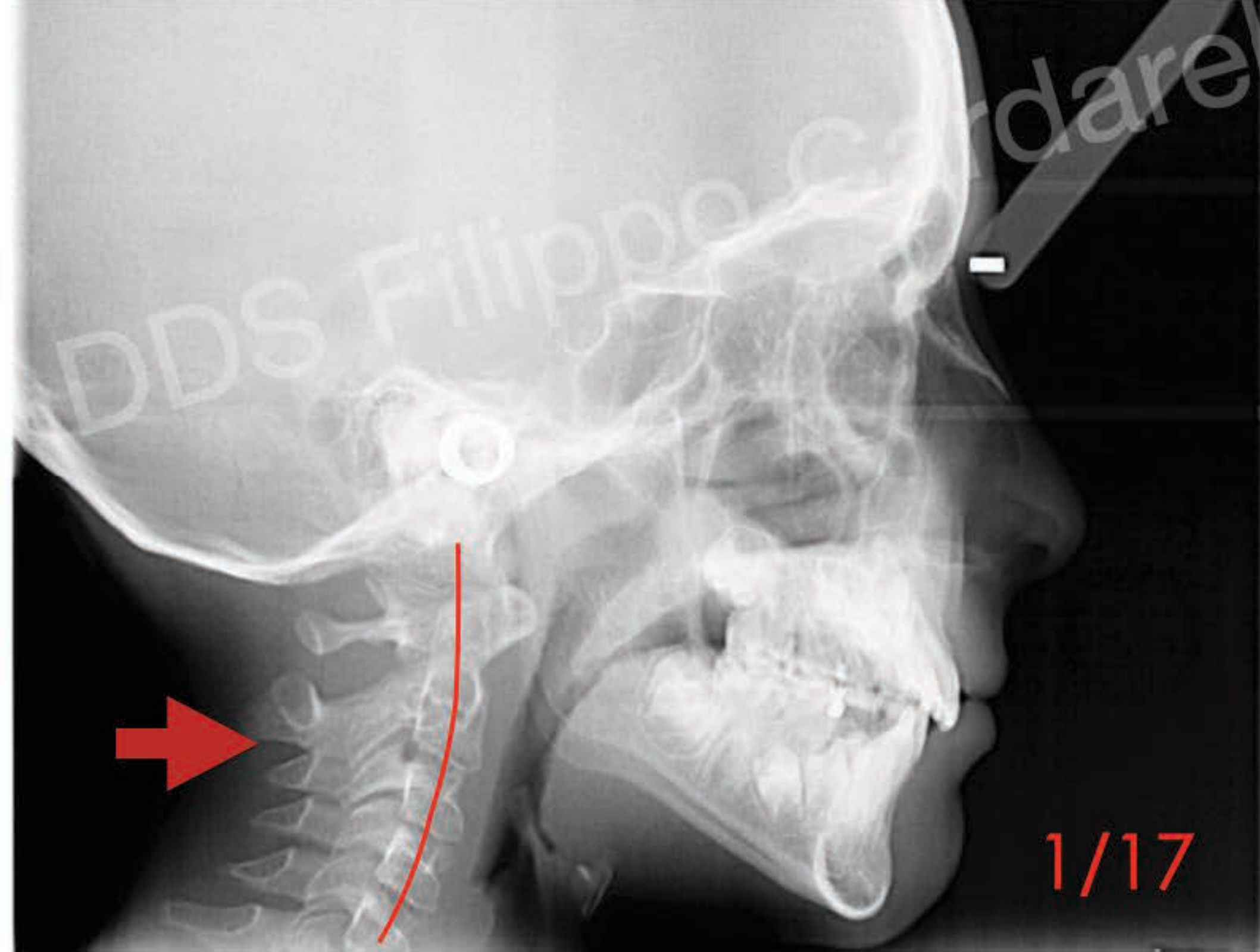
DDS Filippo Cardarelli

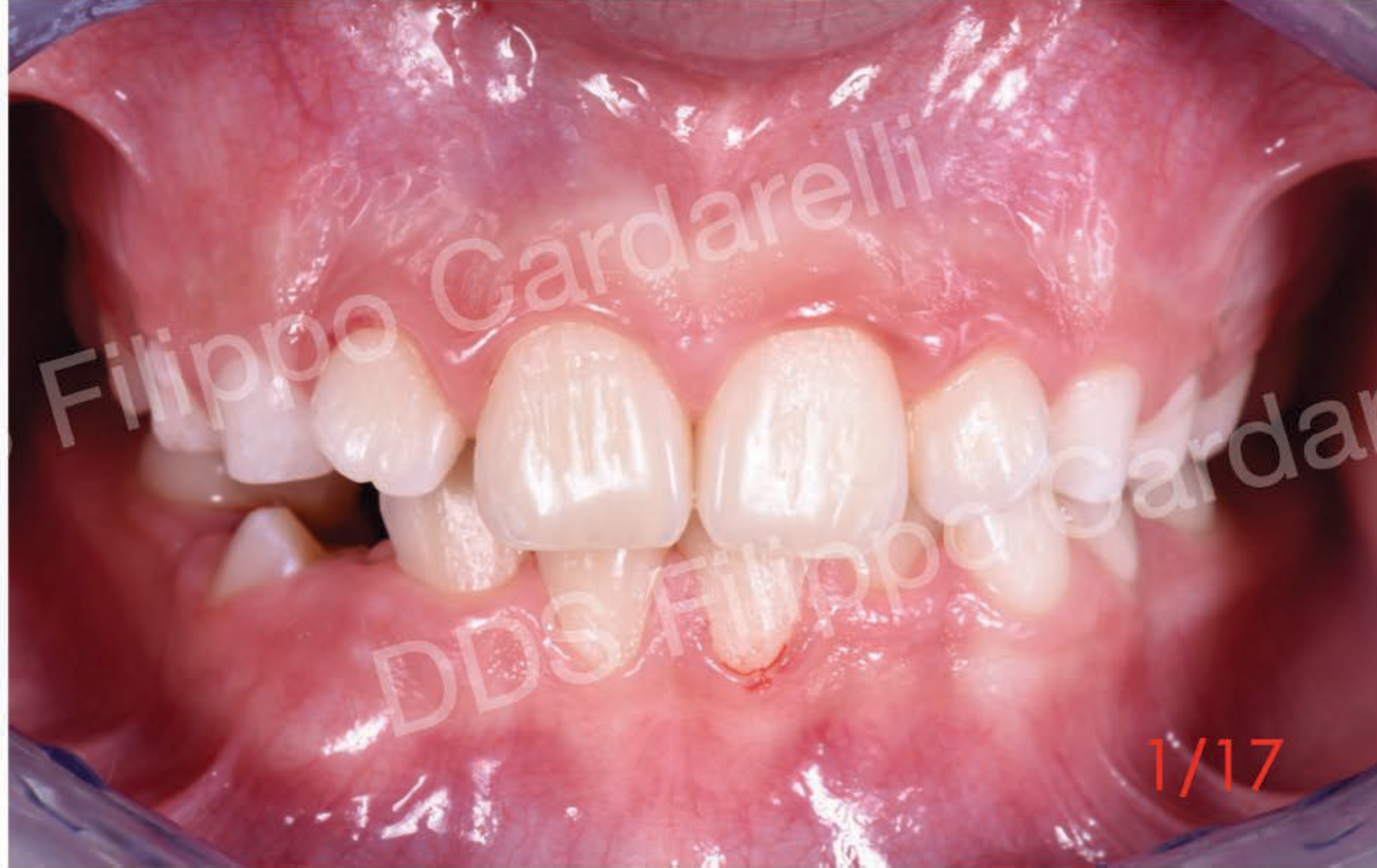






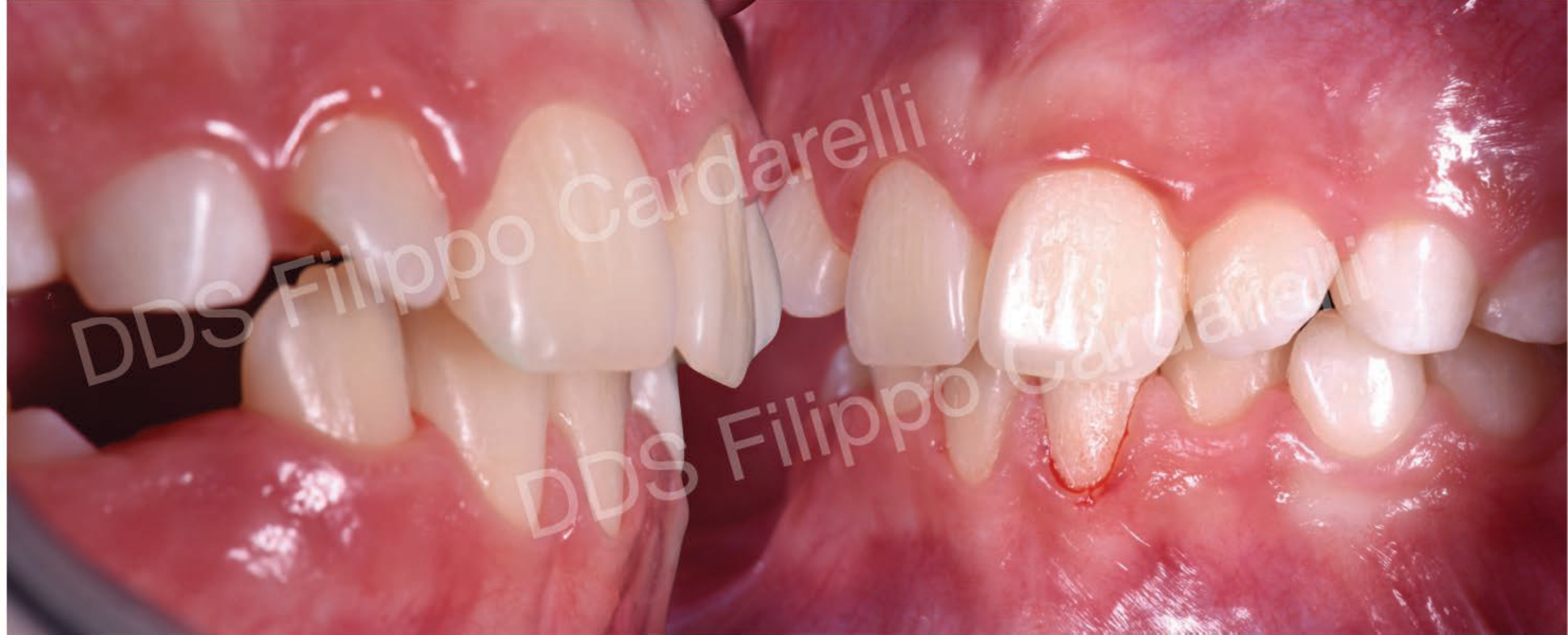




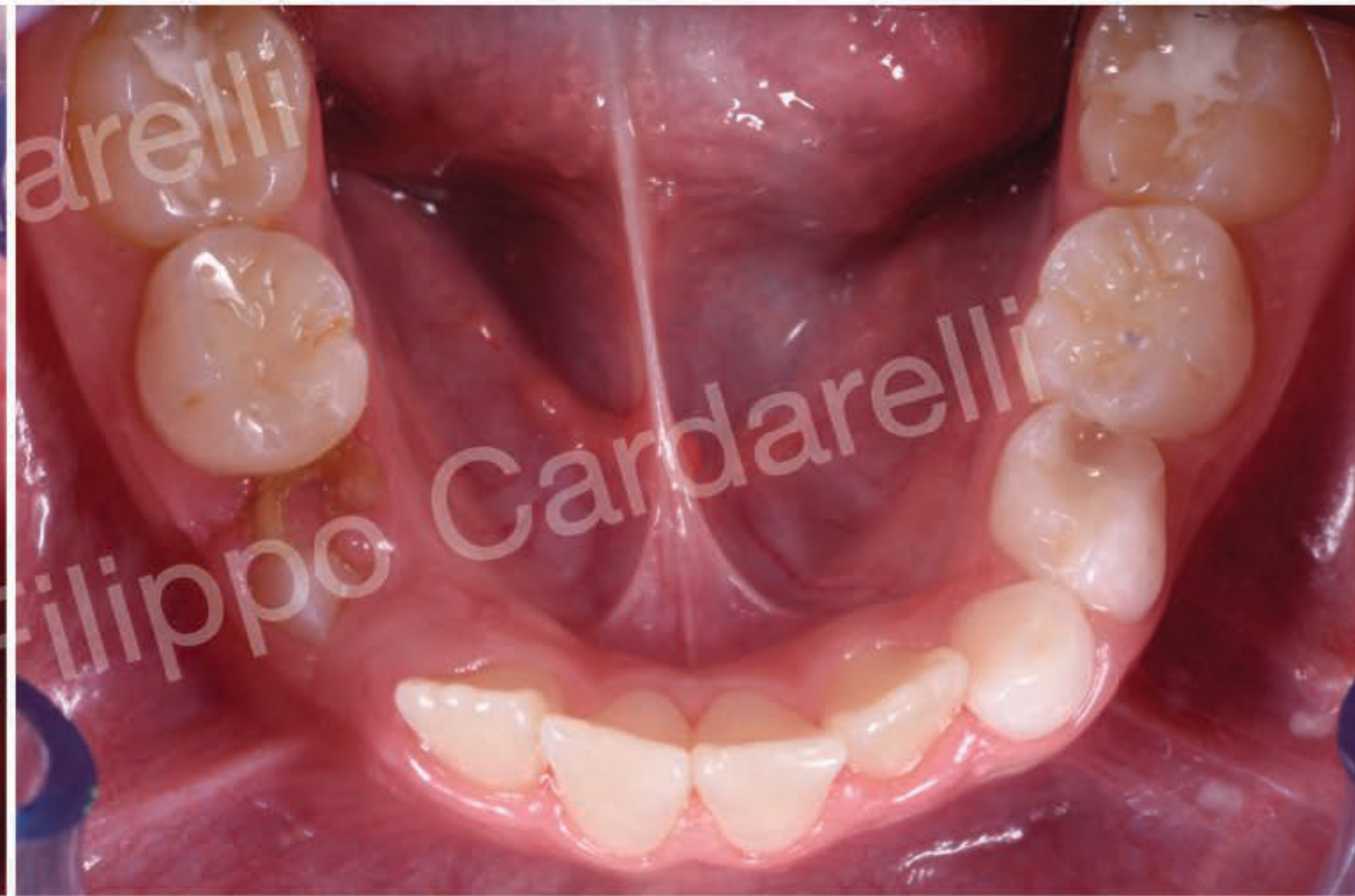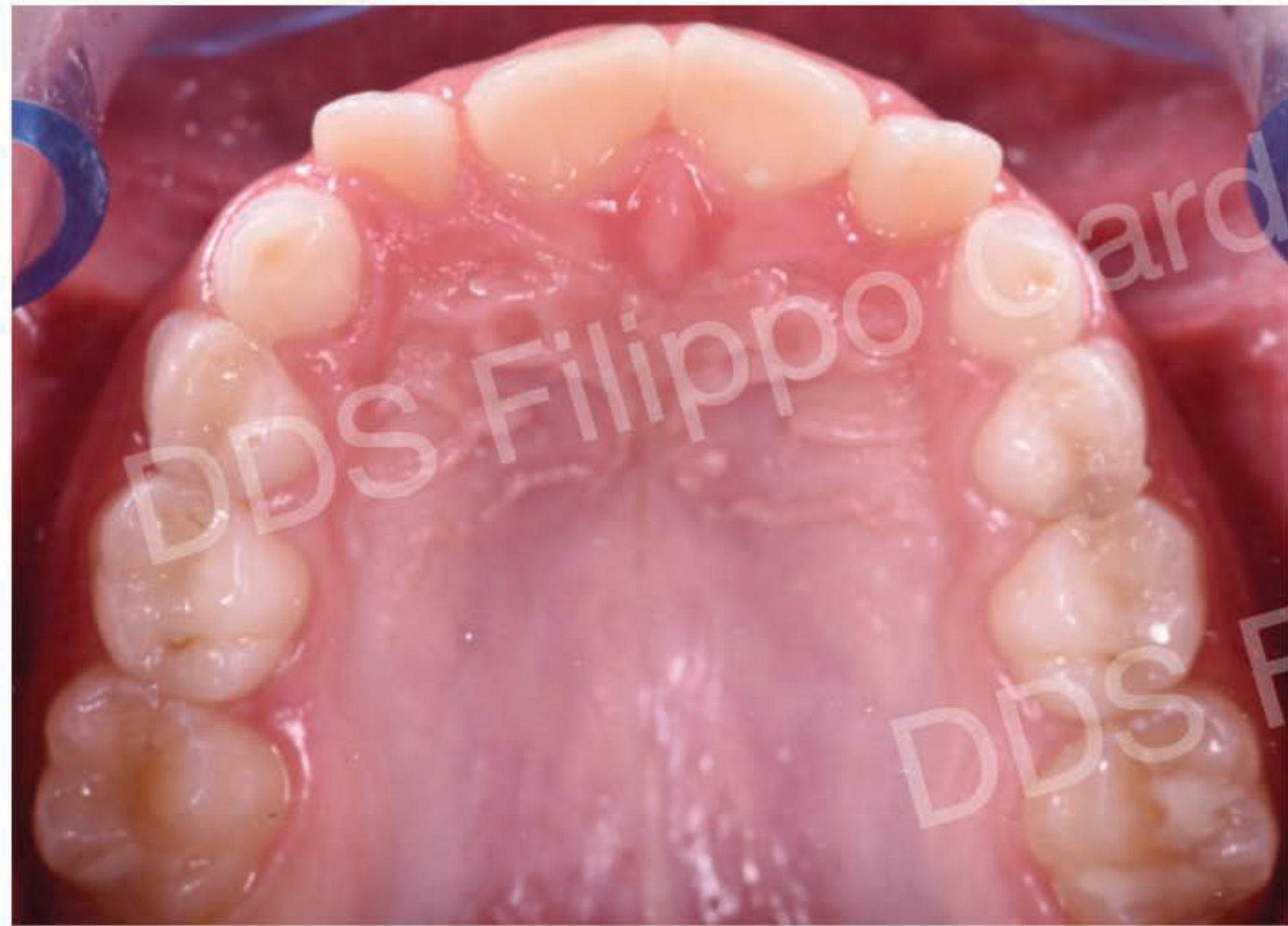1/17

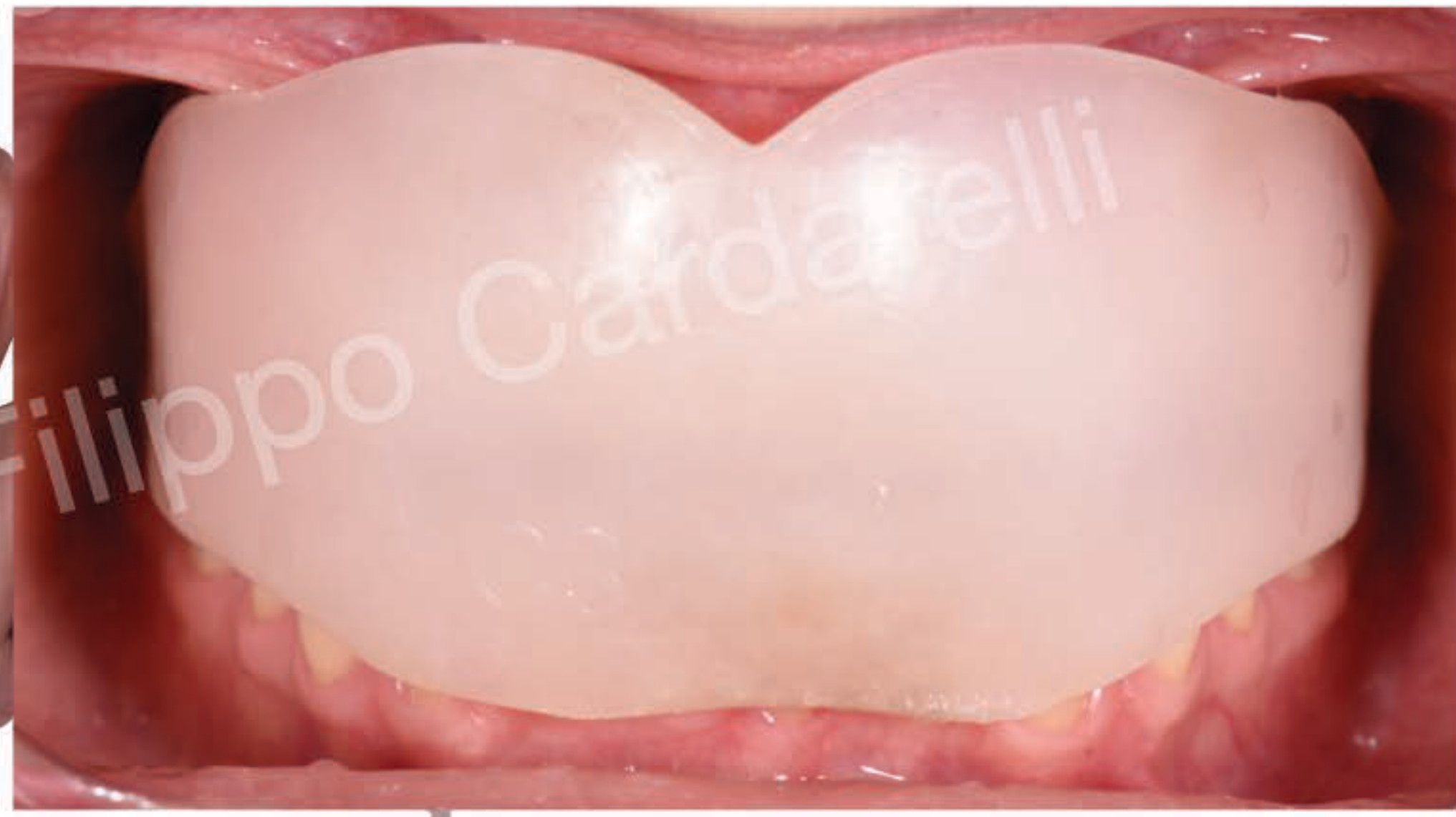
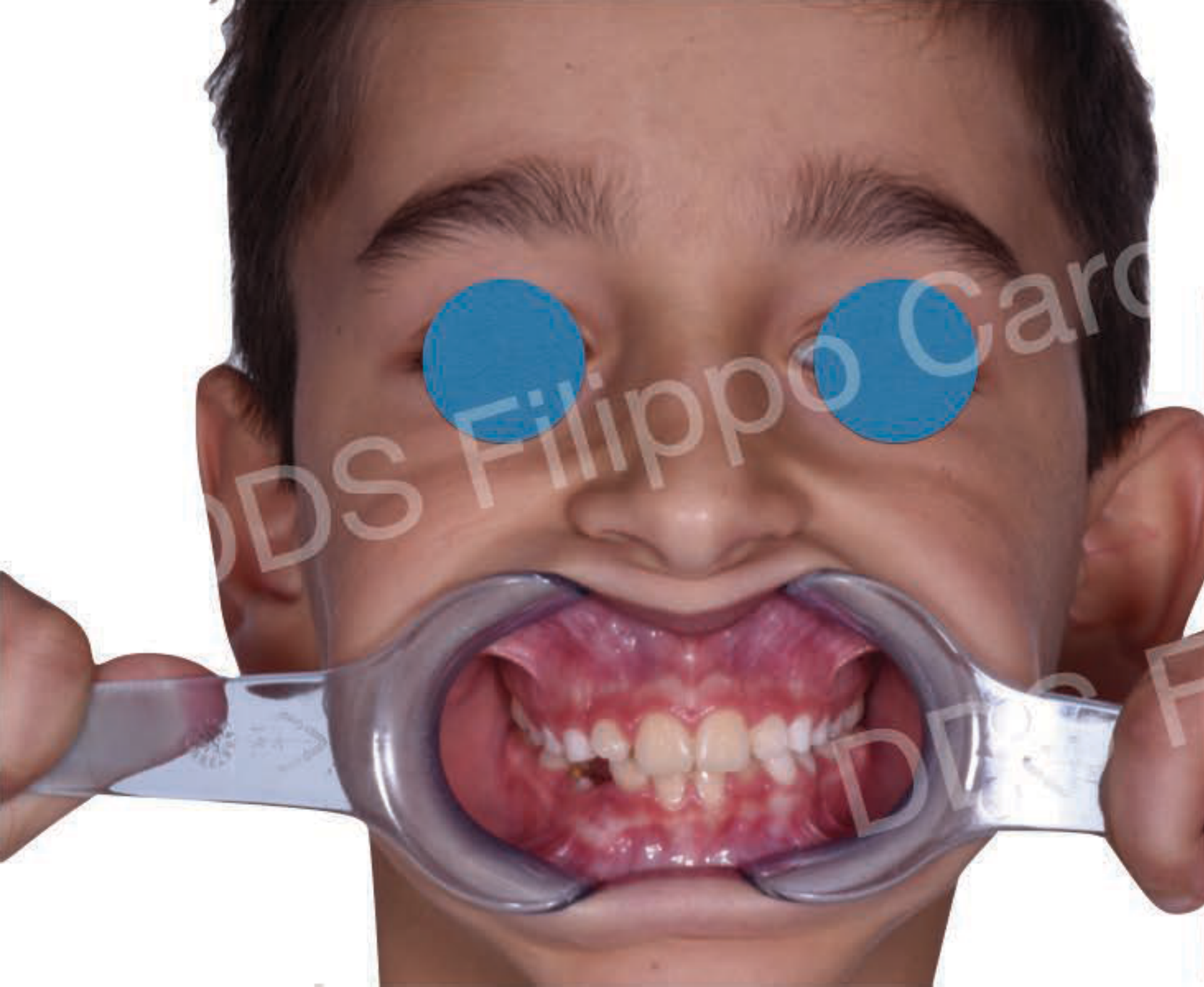


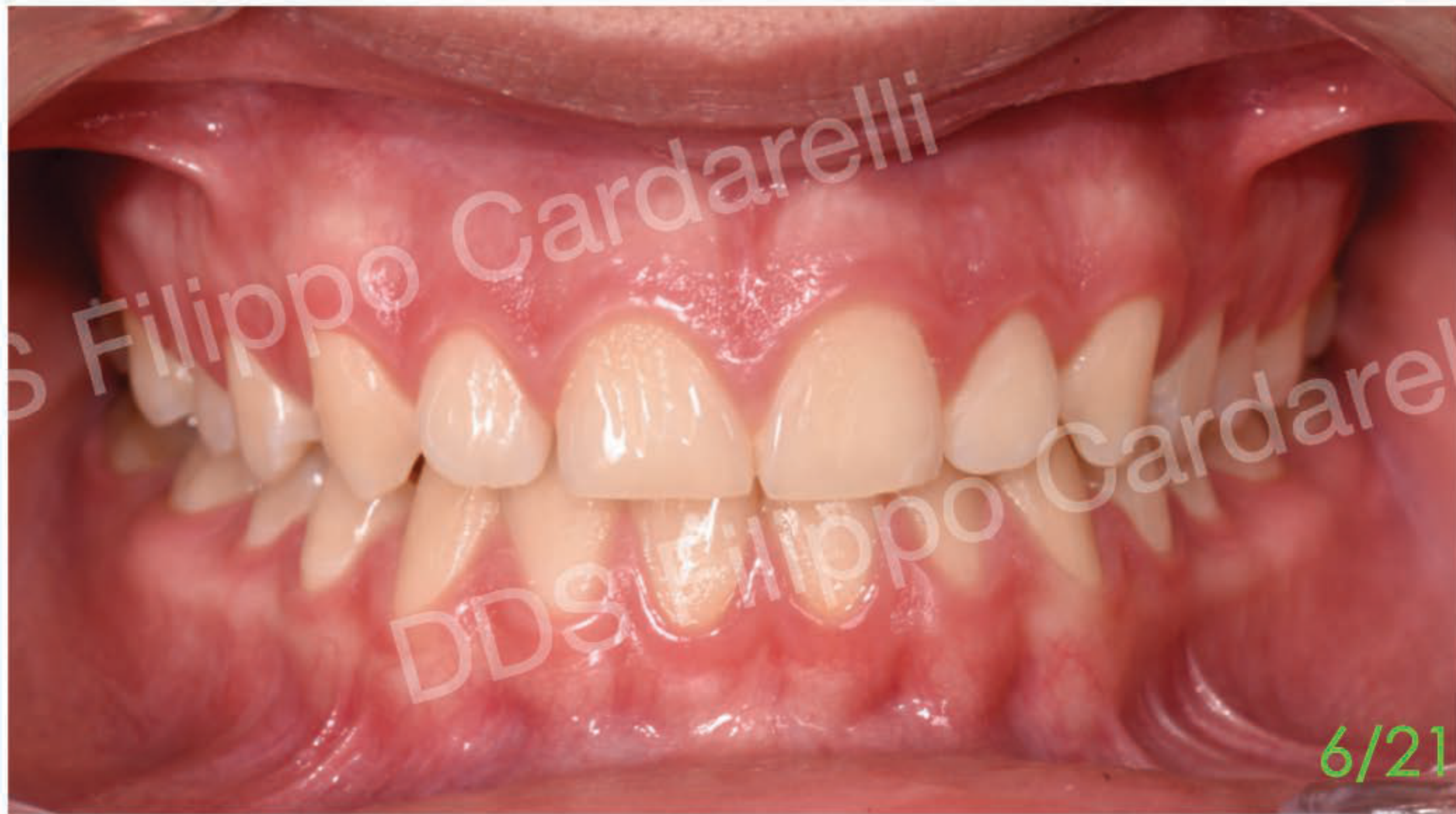






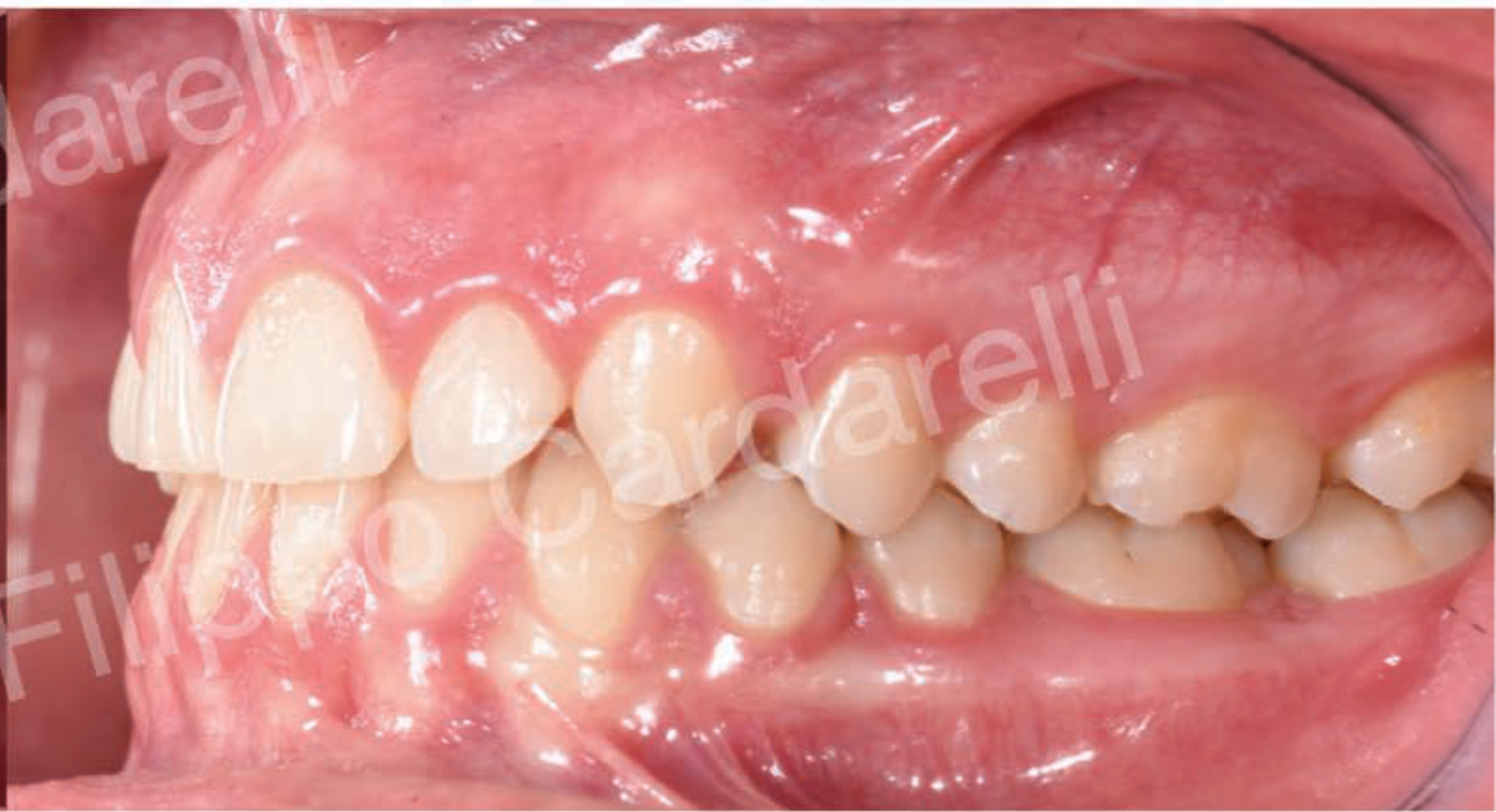
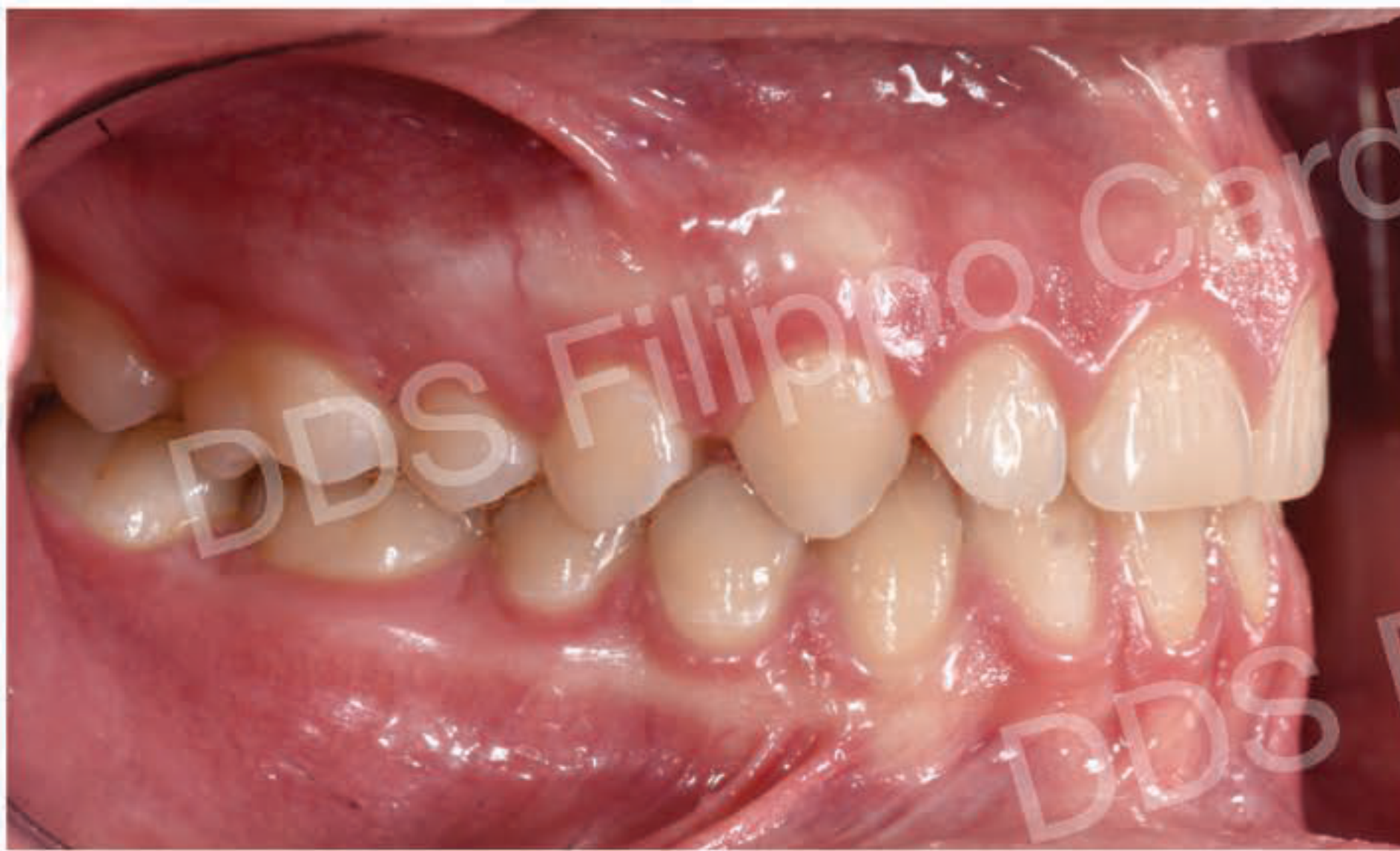

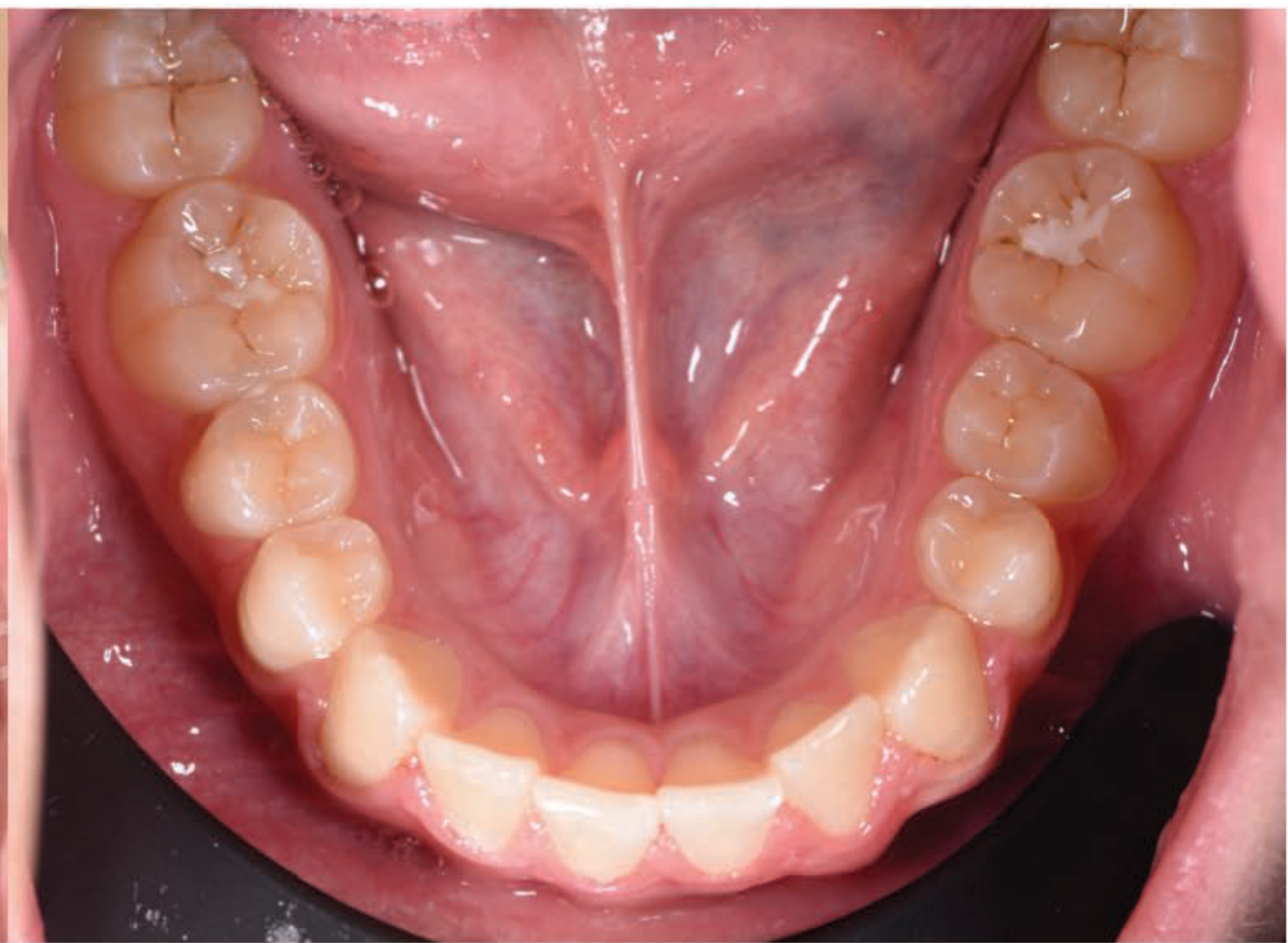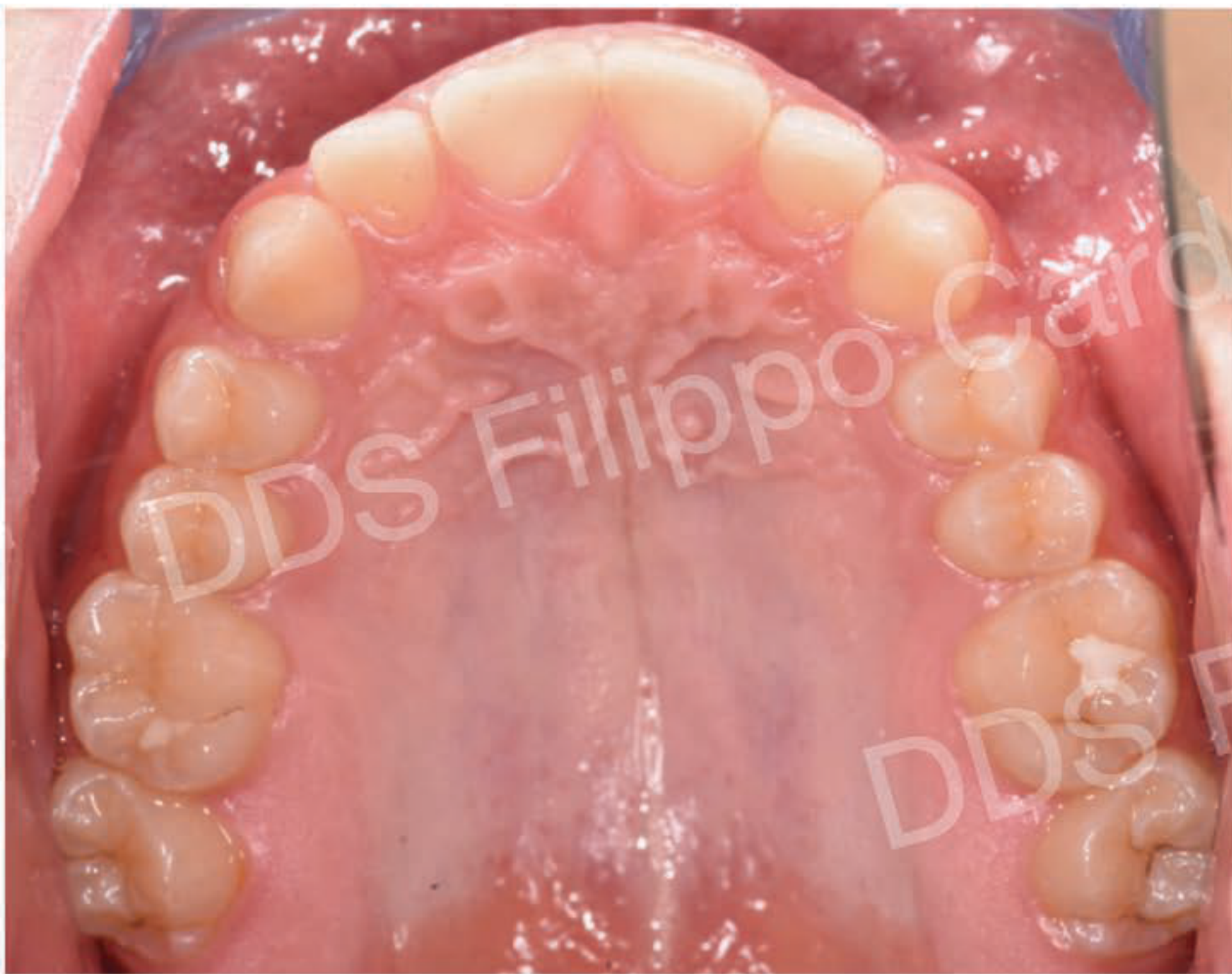6/21

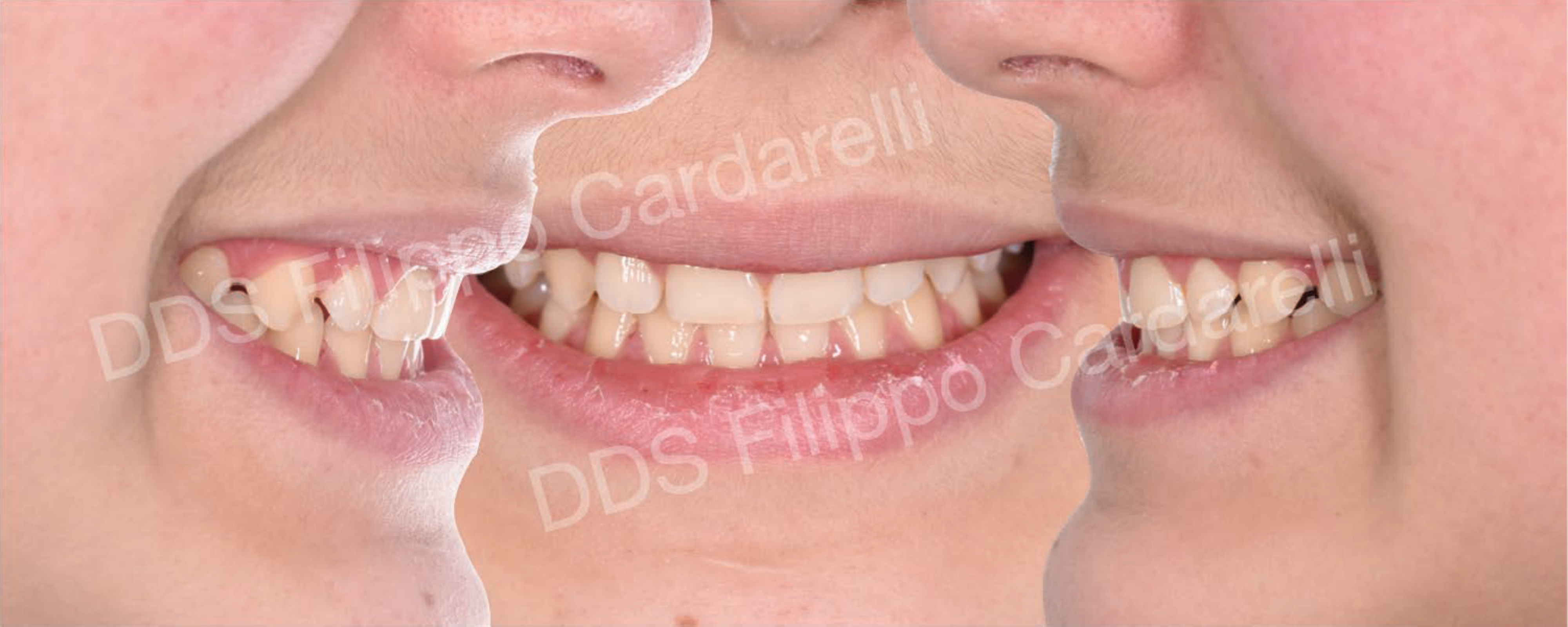




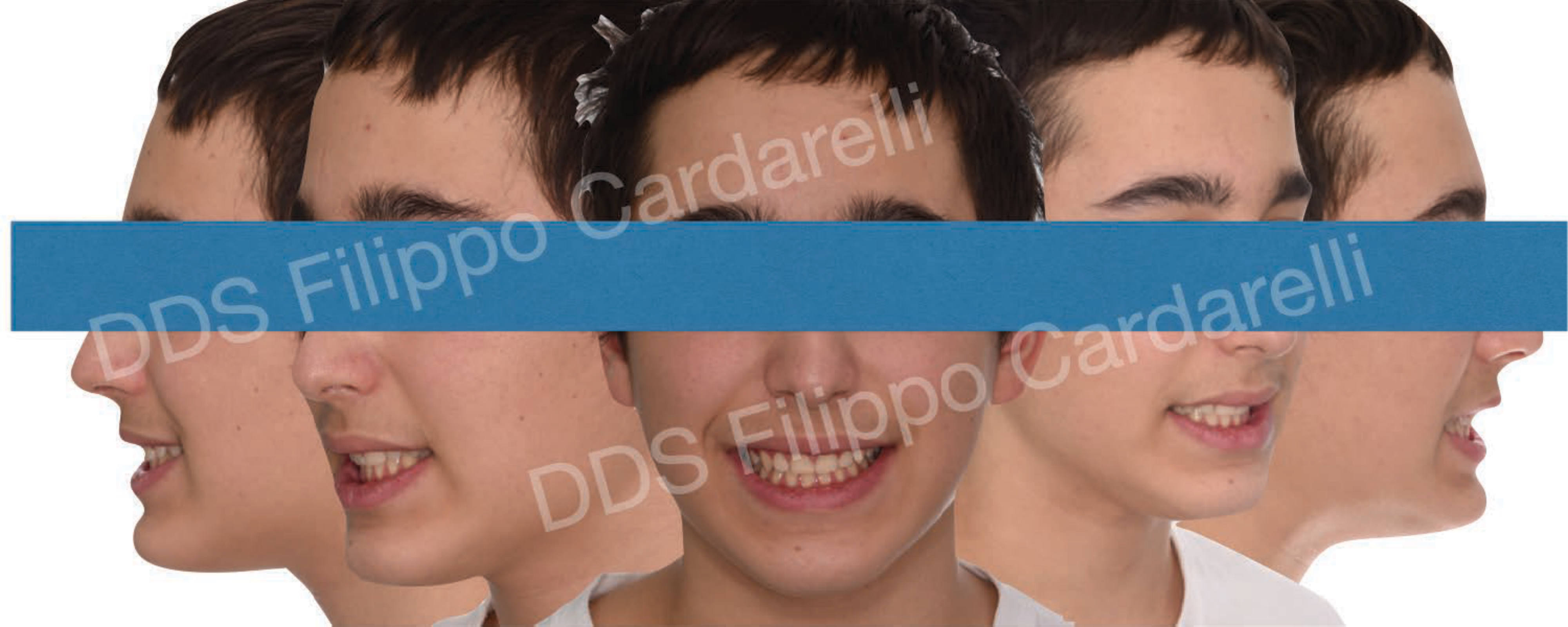


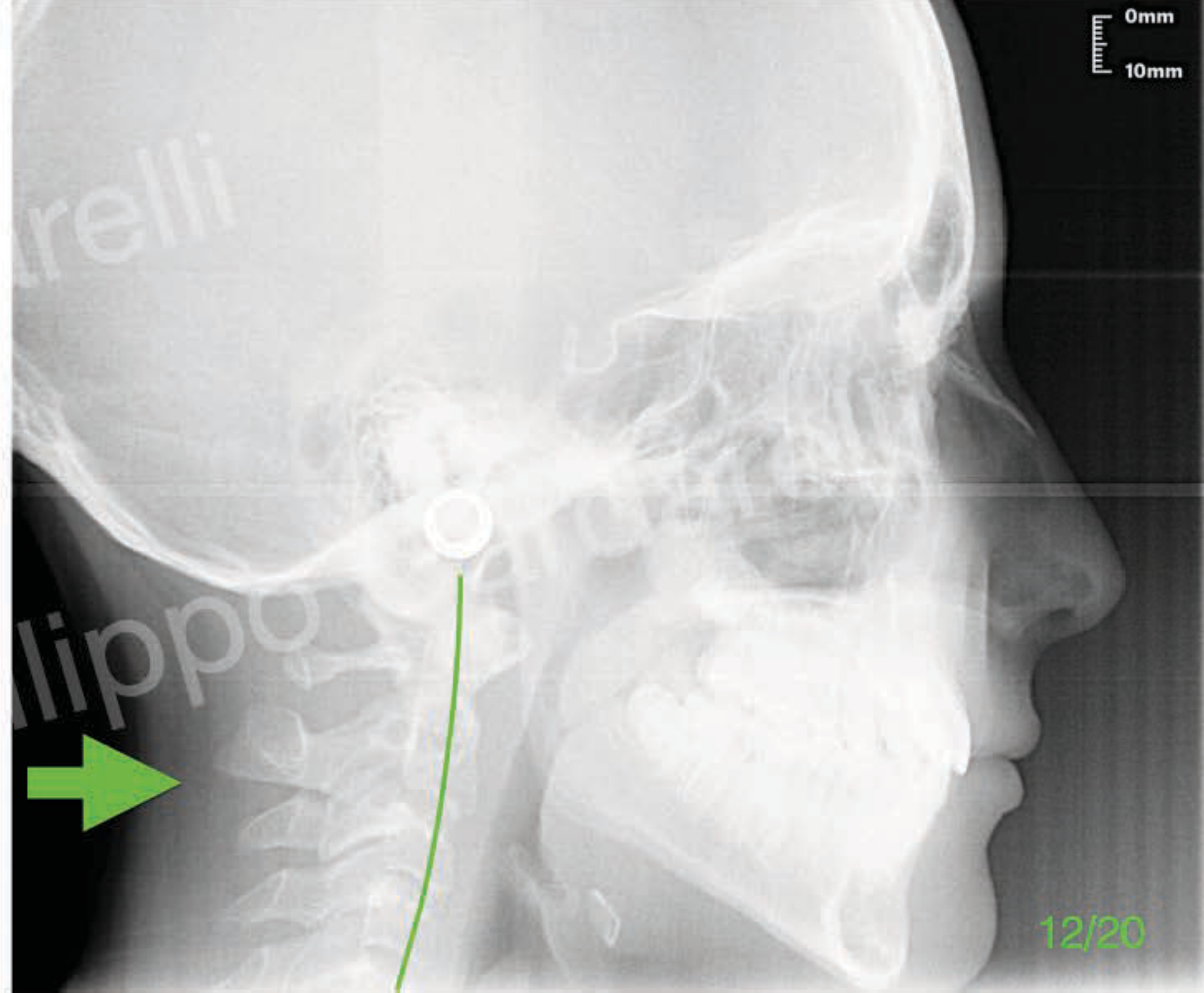
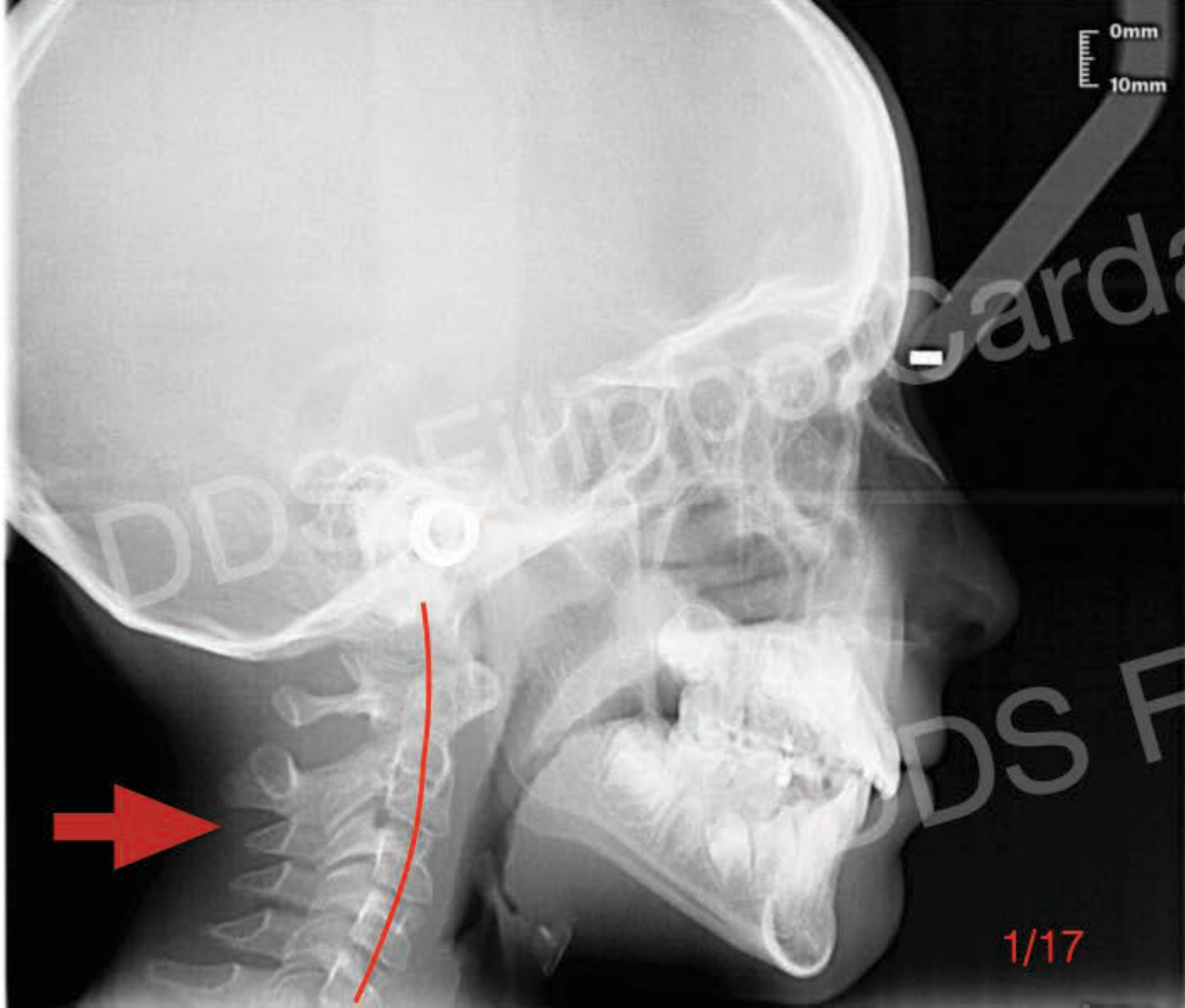






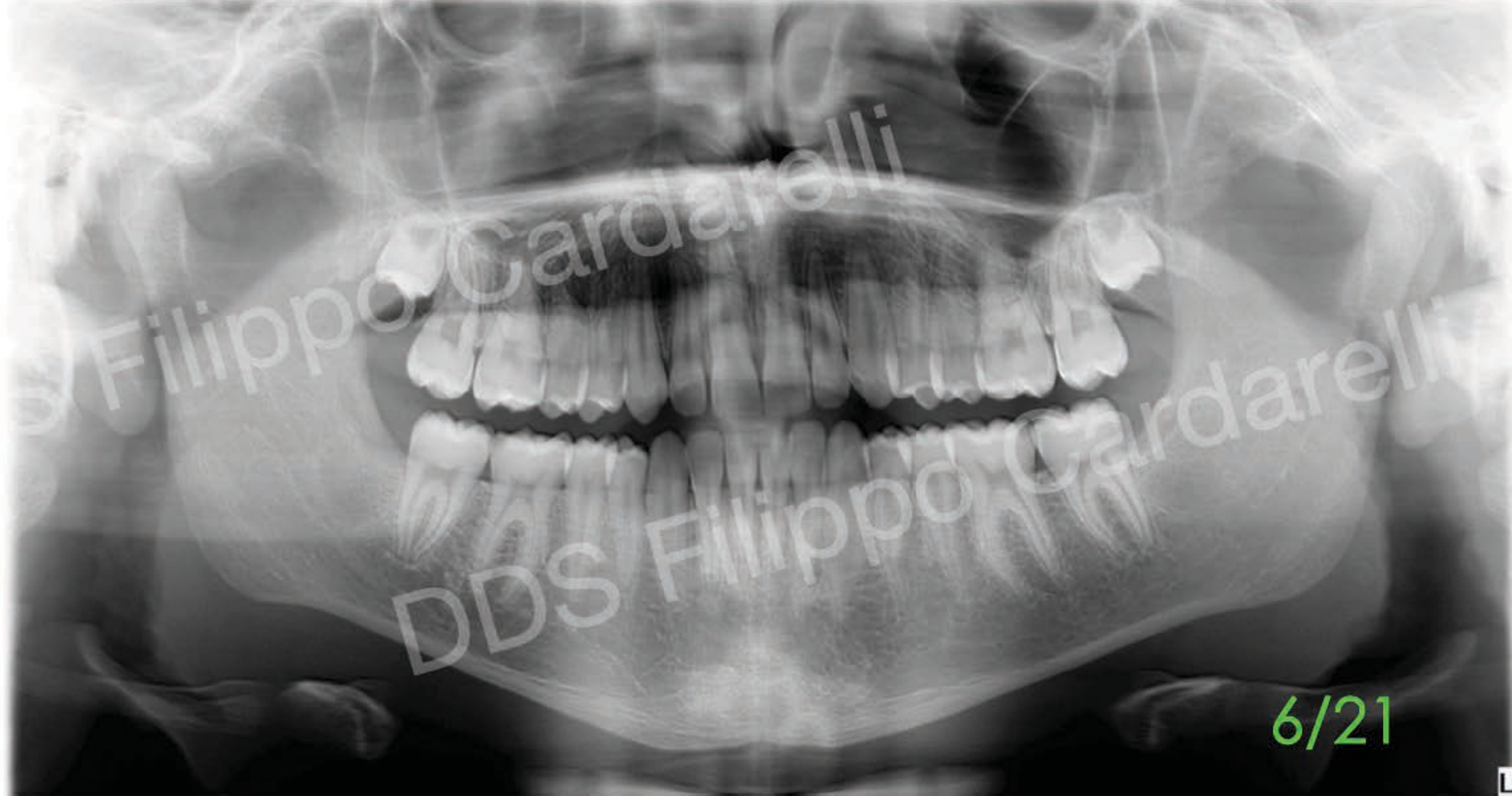









6/21



# Conclusions

The use of elastodontic therapy for the resolution of skeletal problems such as maxillary protrusion and for the resolution of dental problems such as crowding, finds great advantage today due to the integral mastication plan that can promote the guidance of eruption of permanent dental elements and proper intercuspatation.